

# Is Vertebral Augmentation the Right Choice for Cancer Patients With Painful Vertebral Compression Fractures?

Ioannis D. Papanastassiou, MD<sup>a,b</sup>; Kamran Aghayev, MD<sup>a</sup>; James R. Berenson, MD<sup>c</sup>; Meic H. Schmidt, MD<sup>d</sup>; and Frank D. Vrionis, MD, MPH, PhD<sup>a</sup>

## Abstract

Cancer-related fractures of the spine are different from osteoporotic ones, not only in pathogenesis but also in natural history and treatment. Higher class evidence now supports offering balloon kyphoplasty to a patient with cancer, provided that the pain is significant in intensity, has a positional character, and correlates to the area of the fractured vertebrae. Absence of clinical spinal cord compression and overt instability are paramount. Because of the frequent disruption of the posterior vertebral body cortex in these patients, the procedure should be performed by experienced operators who could also quickly perform an open decompression if cement extravasation occurs. Patients will benefit from vertebral augmentation, even in chronic malignant fractures. A biopsy should be routinely performed and a combination with radiation treatment would be beneficial in most cases. (*JNCCN* 2012;10:715–719)

Almost 3 years ago, the International Myeloma Working Group published a statement and raised some questions regarding the treatment of cancer-related fractures with vertebral augmentation procedures (VAPs). Some of those issues included indications, patient selection, preferred procedure (balloon kyphoplasty [BKP] vs. vertebroplasty [VP]), optimal intervention time, and alternatives.<sup>1</sup>

Among patients with cancer with vertebral compression fractures (VCFs), many retrospective or single-

arm prospective studies have reported good results with VP, and especially BKP.<sup>1–8</sup> However, results of the first randomized trial (Cancer Fracture Evaluation [CAFE] study) are now available, which show the superiority of immediate BKP compared with nonsurgical management.<sup>9</sup> This prospective, randomized, multicenter study involved 134 patients assigned either to kyphoplasty (n = 70) or as controls (n = 64). The results of the CAFE study strongly favor kyphoplasty in terms of pain and disability reduction, improvement in quality of life, and decrease in analgesic use. More than half of the patients in the control group (n = 38) crossed over to the kyphoplasty group after the 1-month assessment, with similar outcomes as those seen in the original kyphoplasty group.

VAPs have many advantages, including immediate impact, reduced mortality,<sup>10</sup> avoidance of deleterious effects of prolonged recumbency, more cost-effectiveness compared with conservative management,<sup>11</sup> minimally invasive nature requiring outpatient care in most cases, biopsy, restoration of vertebral height,<sup>12</sup> and potential antitumor effect of methylmethacrylate monomer and the heat generated by its polymerization.<sup>13</sup> In selected cases, VAPs can also be combined with radiofrequency ablation to achieve better local tumor control.<sup>13,14</sup> Rare complications of VAPs include cement leakage to canal/foramen,<sup>15</sup> pulmonary embolism,<sup>16</sup> osteomyelitis,<sup>17</sup> pneumothorax, and retroperitoneal haematoma.<sup>1</sup> Most studies report higher rates of cement leakage with VP<sup>15,18</sup> and better kyphosis reduction with BKP,<sup>12,19</sup> whereas BKP is more expensive.

Because of the randomized trials that showed no benefit of VP compared with a sham procedure<sup>17,20</sup> or conservative management,<sup>21</sup> the value of VP in treating osteoporotic vertebral fractures has been questioned. Therefore, the American Academy of Orthopedic

From <sup>a</sup>H. Lee Moffitt Cancer Center & Research Institute, Tampa, Florida; <sup>b</sup>General Oncological Hospital "Agioi Anargyroi", Athens, Greece; <sup>c</sup>Institute for Myeloma & Bone Cancer Research, West Hollywood, California; and <sup>d</sup>Department of Neurosurgery, University of Utah, Salt Lake City, Utah.

Submitted April 19, 2011; accepted for publication October 7, 2011.

Drs. Papanastassiou, Aghayev, and Schmidt have disclosed that they have no financial interests, arrangements, or affiliations with the manufacturers of any products discussed in this article or their competitors. Drs. Berenson and Vrionis have disclosed that they are consultants for Medtronic and have received research grants and honoraria.

Correspondence: Ioannis D. Papanastassiou, MD, H. Lee Moffitt Cancer Center, 12902 Magnolia Drive, Tampa, FL 33612.  
E-mail: ioannis.papanastassiou@gmail.com

Papanastassiou et al.

Surgeons published guidelines against using VP in osteoporotic fractures.<sup>22</sup> Furthermore, a retrospective analysis in a wide Medicare population claimed that BKP reduced mortality significantly more than nonsurgical management and VP.<sup>23</sup> In the cancer population, both procedures have been regarded as effective, with only one nonrandomized study reporting better results at 6 months and 1 year with BKP versus VP in patients with myeloma.<sup>5</sup> The randomized CAFE trial now provides strong evidence for the superiority of BKP versus nonsurgical management; no randomized studies of VP in the cancer setting nor randomized controlled trials comparing VP with BKP have been published. For the reasons mentioned (more cement leakage with VP, better reduction of kyphosis/mortality benefit from BKP, and lack of randomized controlled trials supporting VP in patients with cancer), the authors favor BKP, especially in patients with significantly collapsed vertebrae<sup>5</sup> or fractures in high stress areas, such as the thoracolumbar junction.<sup>9</sup> However, they do perform VP for nonindex fractures or nondeformed vertebrae to avoid unnecessary cost, but ultimately this is largely operator-dependent.

The optimal time of VAPs is still debated. Although in the osteoporotic population earlier intervention may yield superior results<sup>16,17,24–26</sup> and most authorities advocate a 6- to 8-week conservative trial in mild cases<sup>27</sup> because recovery is anticipated with time, this may not be the case in malignant fractures. Patients with cancer have a less favorable natural course because of the increased rate of bone loss from tumor osteolysis, chemotherapy, radiation therapy (RT), gonadal ablation, compromised medical status, poor nutrition, generalized osteoporosis, and chronic steroid use. Additionally, they are less amenable to conservative treatment and prolonged immobilization, have limited expected survival, and their overall poor functional status interferes with the ability to administer other antineoplastic therapies. Therefore, a VAP should be offered to any patient who presents with significant pain (visual analog scale  $\geq 4$ ) that corresponds with the clinical examination and correlates with positive findings on MRI (edema on short-tau inversion recovery images). In older fractures, the improvement from BKP intervention may still be satisfactory.<sup>28</sup> In fact, in the cancer fracture literature, most of the procedures were performed on subacute or chronic fractures.<sup>3,4,7–9</sup>

In the CAFE trial, the patients who crossed over from nonsurgical management to undergo BKP after 1 month reported comparable results to those who were initially randomized to BKP, indicating that BKP is still beneficial in older fractures.<sup>9</sup>

Experience has taught that some of the contraindications reported previously<sup>17,29</sup> now appear relative, such as canal encroachment,<sup>30,31</sup> and upper thoracic<sup>31</sup> or even cervical<sup>32</sup> location of the fracture. With attention to detail and the advent of accessory tools, such as neuromonitoring and individualized techniques, indications are expanding and surgeons are challenging traditional notions that have previously deterred surgeons from using BKP in certain situations. Part of the reason is that these patients frequently cannot medically withstand the rigors of an open vertebrectomy.

Vertebral height restoration is another factor favoring VAPs. Theoretically it should prevent a domino effect through reducing overall kyphosis. In the CAFE study, rates of subsequent nonindex VCF in kyphoplasty and control groups were similar, despite significant restoration of vertebral height.<sup>9</sup>

A biopsy of the affected vertebrae should be performed concurrently with these procedures. The results may provide significant information regarding future treatment, confirm the presence of metastasis, or reveal a new neoplasm, while not adding to the morbidity of the operation.<sup>33</sup> In fact, patients with cancer may develop VCFs because of a variety of causes, such as osteoporosis, prolonged steroid use, chemotherapy, or RT. Therefore, verification of metastasis provided by biopsy is not only important for staging purposes but may also preclude the use of additional treatments, such as RT. In a recent institutional review, only 50% of patients with cancer with VCFs had biopsy results showing malignant disease.<sup>8</sup> A biopsy is also of paramount importance in cases of multiple primaries or when the VCF represents the first sign of metastasis after a long latency period.<sup>33–35</sup>

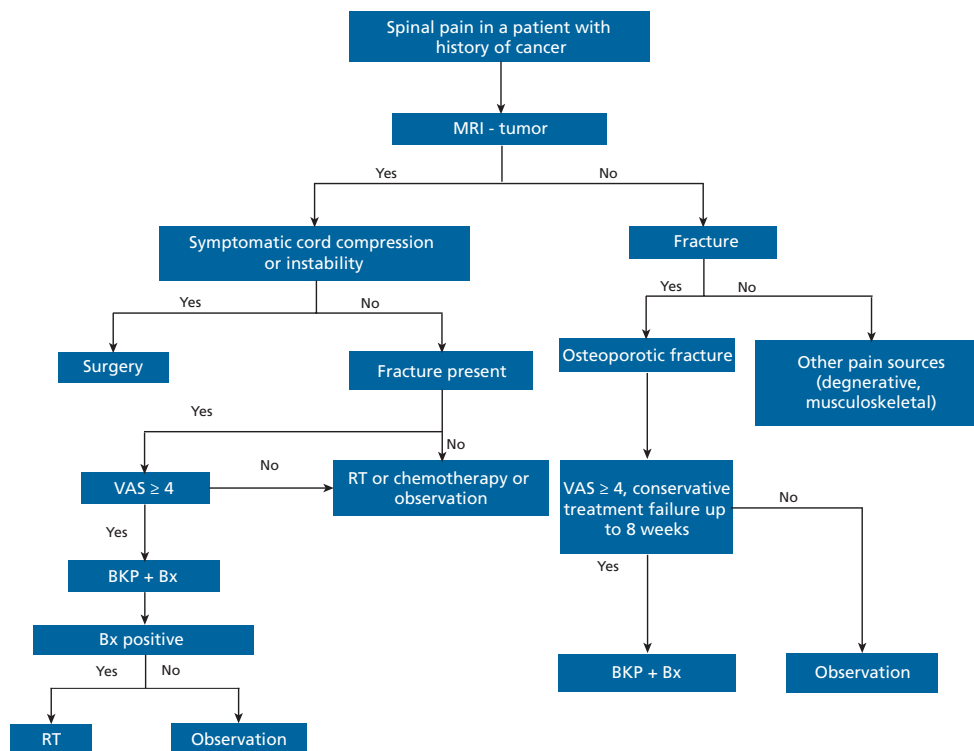
The number of levels that may be safely performed in each session has not been defined; most authorities feel that up to 3 (or 4) levels may be safely performed without significantly increasing the length or morbidity of the operation.<sup>1,8,9</sup> The authors frequently perform VAPs for impending or intervening vertebrae, especially when kyphosis is present or if cement extravasation occurs in the disk space (increasing the risk for adjacent fracture).<sup>36</sup>

## Vertebral Augmentation in Cancer Compression Fractures

Finally, regarding the relation of VAPs to RT, the authors believe they are complimentary treatments; although cement augmentation may exert a tumoricidal effect (toxic monomer and heat), the issue of effectively treating the underlying tumor cells within the vertebrae remains.<sup>37</sup> Therefore, RT should be offered to some of these patients. However, RT alone may be insufficient to control the pain and will not address painful mechanical instability.<sup>37</sup> In fact, RT is known to produce detrimental bone effects, including damage to the cellular and vascular bony elements and alteration of biomechanical properties in doses of 20 to 30 Gy.<sup>38,39</sup> Rose et al.<sup>40</sup> found a 39% chance of fracture after intensity-modulated RT for spinal metastasis. A combination of BKP and intensity-modulated RT may be a new treatment paradigm for some patients with malignant disease in the fractured vertebral body.<sup>41</sup> However, the sequence must be determined and made on an individualized basis, because no studies delineating this issue are currently available. Oncologists must weigh the potential benefits against the deleterious effects of RT to the affected vertebral body and adjacent organs and, importantly, bone marrow function, which

may compromise the ability to administer more important systemic therapeutic modalities required to treat patients with metastatic cancer or multiple myeloma.

In conclusion, cancer-related fractures of the spine are different from osteoporotic ones, not only in pathogenesis but also in natural history and treatment. Class 1 to 2 evidence now supports offering a VAP to a patient with cancer, provided that the pain is significant in intensity, has a positional character (i.e., increases with axial loading), and correlates to the area of the fractured vertebrae. Patients will benefit from vertebral augmentation, even in chronic malignant fractures.<sup>4,6,9</sup> Figure 1 provides a proposed therapeutic algorithm for those fractures. Absence of clinical spinal cord compression and overt instability are paramount. Because of the frequent disruption of the posterior vertebral body cortex in these patients, the procedure should be performed by experienced operators who could also quickly perform an open decompression if cement extravasation occurs, or else a spine surgeon should be available in case complications occur. A biopsy should routinely be performed and a combination with RT would be benefi-



**Figure 1** Algorithm for treatment of vertebral compression fractures.

Abbreviations: BKP, balloon kyphoplasty; Bx, biopsy; RT, radiation treatment; VAS, visual analog score.

cial in most cases. Given the improvement in quality of life that this minimally invasive procedure offers to patients with cancer, it should be considered and discussed, when appropriate, in lieu of open maximally invasive surgeries or pain ablation procedures.

## References

- Hussein MA, Vrionis FD, Allison R, et al. The role of vertebral augmentation in multiple myeloma: International Myeloma Working Group consensus statement. *Leukemia* 2008;22:1479–1484.
- Lieberman I, Reinhardt MK. Vertebroplasty and kyphoplasty for osteolytic vertebral collapse. *Clin Orthop Relat Res* 2003;415:S176–186.
- Fourney DR, Schomer DF, Nader R, et al. Percutaneous vertebroplasty and kyphoplasty for painful vertebral body fractures in cancer patients. *J Neurosurg* 2003;98:21–30.
- Lane JM, Hong R, Koob J, et al. Kyphoplasty enhances function and structural alignment in multiple myeloma. *Clin Orthop Relat Res* 2004;426:49–53.
- Kose KC, Cebesoy O, Akan B, et al. Functional results of vertebral augmentation techniques in pathological vertebral fractures of myelomatous patients. *J Natl Med Assoc* 2006;98:1654–1658.
- Pflugmacher R, Taylor R, Agarwal A, et al. Balloon kyphoplasty in the treatment of metastatic disease of the spine: a 2-year prospective evaluation. *Eur Spine J* 2008;17:1042–1048.
- Dudeney S, Lieberman IH, Reinhardt MK, et al. Kyphoplasty in the treatment of osteolytic vertebral compression fractures as a result of multiple myeloma. *J Clin Oncol* 2002;20:2382–2387.
- Vrionis FD, Hamm A, Stanton N, et al. Kyphoplasty for tumor-associated spinal fractures. *Tech Reg Anesth Pain Manag* 2005;9:35–39.
- Berenson J, Pflugmacher R, Jarzem P, et al. Balloon kyphoplasty versus non-surgical fracture management for treatment of painful vertebral body compression fractures in patients with cancer: a multicentre, randomised controlled trial. *Lancet Oncol* 2011;12:225–235.
- Edidin AA, Ong KL, Lau E, et al. Mortality risk for operated and non-operated vertebral fracture patients in the medicare population. *J Bone Miner Res* 2011;26:1617–1626.
- Strom O, Leonard C, Marsh D, et al. Cost-effectiveness of balloon kyphoplasty in patients with symptomatic vertebral compression fractures in a UK setting. *Osteoporos Int* 2010;21:1599–1608.
- Liu JT, Liao WJ, Tan WC, et al. Balloon kyphoplasty versus vertebroplasty for treatment of osteoporotic vertebral compression fracture: a prospective, comparative, and randomized clinical study. *Osteoporos Int* 2010;21:359–364.
- Aghayev K, Papanastassiou ID, Vrionis F. Role of vertebral augmentation procedures in the management of vertebral compression fractures in cancer patients. *Curr Opin Support Palliat Care* 2011;5:222–226.
- Katonis P, Pasku D, Alpentaki K, et al. Treatment of pathologic spinal fractures with combined radiofrequency ablation and balloon kyphoplasty. *World J Surg Oncol* 2009;7:90.
- Taylor RS, Taylor RJ, Fritzell P. Balloon kyphoplasty and vertebroplasty for vertebral compression fractures: a comparative systematic review of efficacy and safety. *Spine (Phila Pa 1976)* 2006;31:2747–2755.
- Klazen CA, Lohle PN, de Vries J, et al. Vertebroplasty versus conservative treatment in acute osteoporotic vertebral compression fractures (Vertos II): an open-label randomised trial. *Lancet* 2010;376:1085–1092.
- Buchbinder R, Osborne RH, Ebeling PR, et al. A randomized trial of vertebroplasty for painful osteoporotic vertebral fractures. *N Engl J Med* 2009;361:557–568.
- Lee MJ, Dumonski M, Cahill P, et al. Percutaneous treatment of vertebral compression fractures: a meta-analysis of complications. *Spine (Phila Pa 1976)* 2009;34:1228–1232.
- Rollinghoff M, Siewe J, Zarghooni K, et al. Effectiveness, security and height restoration on fresh compression fractures—a comparative prospective study of vertebroplasty and kyphoplasty. *Minim Invasive Neurosurg* 2009;52:233–237.
- Kallmes DF, Comstock BA, Heagerty PJ, et al. A randomized trial of vertebroplasty for osteoporotic spinal fractures. *N Engl J Med* 2009;361:569–579.
- Rousing R, Hansen KL, Andersen MO, et al. Twelve-months follow-up in forty-nine patients with acute/semiacute osteoporotic vertebral fractures treated conservatively or with percutaneous vertebroplasty: a clinical randomized study. *Spine (Phila Pa 1976)* 2010;35:478–482.
- Esses SI, McGuire R, Jenkins J, et al. The treatment of symptomatic osteoporotic spinal compression fractures. *J Am Acad Orthop Surg* 2011;19:176–182.
- Edidin AA, Ong KL, Lau E, et al. Mortality risk for operated and nonoperated vertebral fracture patients in the medicare population. *J Bone Miner Res* 2011;26:1617–1626.
- Grafe IA, Da Fonseca K, Hillmeier J, et al. Reduction of pain and fracture incidence after kyphoplasty: 1-year outcomes of a prospective controlled trial of patients with primary osteoporosis. *Osteoporos Int* 2005;16:2005–2012.
- Crandall D, Slaughter D, Hankins PJ, et al. Acute versus chronic vertebral compression fractures treated with kyphoplasty: early results. *Spine J* 2004;4:418–424.
- Pflugmacher R, Kandziora F, Schroder R, et al. Vertebroplasty and kyphoplasty in osteoporotic fractures of vertebral bodies: a prospective 1-year follow-up analysis. *Rofo* 2005;177:1670–1676.
- Brunton S, Carmichael B, Gold D, et al. Vertebral compression fractures in primary care: recommendations from a consensus panel. *J Fam Pract* 2005;54:781–788.
- Kasperk C, Grafe IA, Schmitt S, et al. Three-year outcomes after kyphoplasty in patients with osteoporosis with painful vertebral fractures. *J Vasc Interv Radiol* 2010;21:701–709.
- Wardlaw D, Cummings SR, Van Meirhaeghe J, et al. Efficacy and safety of balloon kyphoplasty compared with non-surgical care for vertebral compression fracture (FREE): a randomised controlled trial. *Lancet* 2009;373:1016–1024.
- Stoffel M, Wolf I, Ringel F, et al. Treatment of painful osteoporotic compression and burst fractures using kyphoplasty: a prospective observational design. *J Neurosurg Spine* 2007;6:313–319.
- Eleraky M, Papanastassiou I, Setzer M, et al. Balloon kyphoplasty in the treatment of metastatic tumors of the upper thoracic spine. *J Neurosurg Spine* 2011;14:372–376.
- Masala S, Anselmetti GC, Muto M, et al. Percutaneous vertebroplasty relieves pain in metastatic cervical fractures. *Clin Orthop Relat Res* 2011;469:715–722.
- Muijs SP, Akkermans PA, van Erkel AR, et al. The value of routinely performing a bone biopsy during percutaneous vertebroplasty in treatment of osteoporotic vertebral compression fractures. *Spine*

## Vertebral Augmentation in Cancer Compression Fractures

- (Phila Pa 1976) 2009;34:2395–2399.
34. Allen RT, Kum JB, Weidner N, et al. Biopsy of osteoporotic vertebral compression fractures during kyphoplasty: unsuspected histologic findings of chronic osteitis without clinical evidence of osteomyelitis. *Spine (Phila Pa 1976)* 2009;34:1486–1491.
  35. Togawa D, Lieberman IH, Bauer TW, et al. Histological evaluation of biopsies obtained from vertebral compression fractures: unsuspected myeloma and osteomalacia. *Spine (Phila Pa 1976)* 2005;30:781–786.
  36. Lin EP, Ekholm S, Hiwatashi A, et al. Vertebroplasty: cement leakage into the disc increases the risk of new fracture of adjacent vertebral body. *AJNR Am J Neuroradiol* 2004;25:175–180.
  37. Gerszten PC, Germanwala A, Burton SA, et al. Combination kyphoplasty and spinal radiosurgery: a new treatment paradigm for pathological fractures. *J Neurosurg Spine* 2005;3:296–301.
  38. Pelker RR, Friedlaender GE, Panjabi MM, et al. Radiation-induced alterations of fracture healing biomechanics. *J Orthop Res* 1984;2:90–96.
  39. Triantafyllou N, Sotiropoulos E, Triantafyllou JN. The mechanical properties of the lyophilized and irradiated bone grafts. *Acta Orthop Belg* 1975;41(Suppl 1):35–44.
  40. Rose PS, Laufer I, Boland PJ, et al. Risk of fracture after single fraction image-guided intensity-modulated radiation therapy to spinal metastases. *J Clin Oncol* 2009;27:5075–5079.
  41. Gerszten PC, Mendel E, Yamada Y. Radiotherapy and radiosurgery for metastatic spine disease: what are the options, indications, and outcomes? *Spine (Phila Pa 1976)* 2009;34:S78–92.